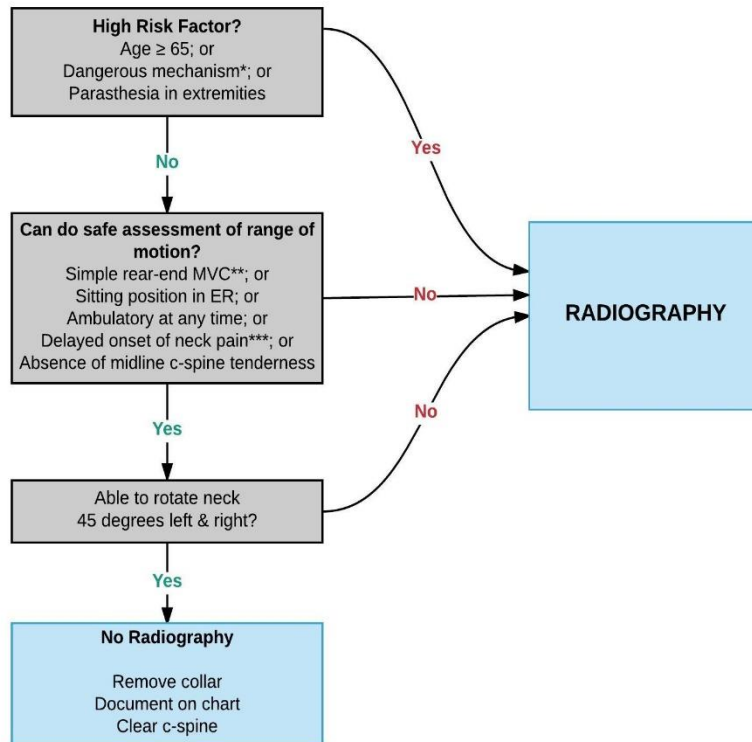


Appendix G: Cervical Spine Imaging with Radiography following the Canadian C-Spine Rule

For alert (GCS=15, absence of intoxication/sedation) and stable patient where cervical spine injury is a concern (adapted from Stiell et al. 2003¹).

Computed tomography (CT) is imaging modality of choice in obtunded patients (GCS<15) and in awake and alert patients who do not clear the Canadian C-Spine Rule. Cervical spine radiographs should have an extremely limited role in trauma imaging due to their relative lack of sensitivity for subtle fractures and injuries compared to CT imaging. Plain film x-rays are indicated only in settings where CT is unavailable and neurologic deficit is suspected based on physical exam, and only if imaging does not delay definitive care.



***Dangerous mechanism:**
- fall from elevation >= 3 feet (or 5 stairs)
- axial load to head, e.g. diving
- MVC high speed (>100km/hr), rollover, ejection
- motorized recreational vehicles
- bicycle collision

****Simple rear-end MVC does NOT include**
- pushed into oncoming traffic
- hit by bus or large truck
- rollover
- hit by high speed vehicle

*****Delayed**
i.e. not immediate onset of neck pain

¹ Stiell IG, Clement CM, McKnight RD, Brison R, Schull MJ, Rowe BH, et al. The Canadian C-Spine Rule versus the NEXUS Low-Risk Criteria in Patients with Trauma. New England Journal of Medicine. 2003 Dec 25;349(26):2510–8.