

# Provincial Clinical Practice Guideline

## Escharotomy for Burn Patients



**CRITICAL CARE BC**  
Provincial Health Services Authority

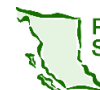**BCEHS** | BC Emergency  
Health Services



**Emergency Care BC**  
Provincial Health Services Authority

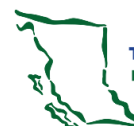

Vancouver Coastal Health



**Provincial Health  
Services Authority**  
Province-wide solutions.  
Better health.

**Vancouver  
CoastalHealth**  
*Promoting wellness. Ensuring care.*



**TRAUMA SERVICES BC**  
Provincial Health Services Authority

## Acknowledgements

---

These guidelines were developed with the collaboration of the members of a multidisciplinary team including Burns and Plastic Surgery, Trauma Services BC, Emergency Care BC, Critical Care BC, British Columbia Emergency Health Services, Provincial Health Services Authority, and Transport Medicine.

Sincere appreciation to Dr. Anthony Papp, MD, PhD, FRCSC, FABA, Plastic Surgeon, Medical Director of the BC Professional Firefighters' Burn Unit, Clinical Professor at the University of British Columbia, President of the Canadian Burn Association, and Editor-in-Chief of BURNS Open; for providing clinical content, editorial assistance, and images to guide landmarking.

Images used in this document may be reproduced in whole or part for study or training purposes subject to the inclusion of an acknowledgment of the source.

# Contents

---

<b>Acknowledgements.....</b>	<b>2</b>
<b>Contents .....</b>	<b>3</b>
<b>Introduction.....</b>	<b>4</b>
<b>Indications &amp; Contraindications .....</b>	<b>5</b>
Indications specific to limb .....	5
Indications specific to chest .....	6
<b>Instruction on Performance.....</b>	<b>7</b>
Before Beginning .....	7
General Considerations .....	7
Limbs .....	7
Chest.....	8
General Notes.....	8
<b>What to avoid .....</b>	<b>9</b>
Lower limbs .....	9
Upper limbs.....	9
Neck.....	9
Risks and complications.....	9
<b>Escharotomy Schema-body .....</b>	<b>10</b>
<b>Escharotomy Schema hand.....</b>	<b>11</b>
<b>Step-by-step Procedure for performing an escharotomy .....</b>	<b>12</b>
Images of upper and lower limb escharotomy.....	13
Image of chest escharotomy.....	14
<b>Escharotomy factsheet .....</b>	<b>15</b>
Aim .....	15
Indications .....	15
Environment .....	15
Equipment.....	15
Procedure.....	15
Post-escharotomy care .....	15
<b>References .....</b>	<b>16</b>

## Introduction

Circumferential deep burns can present as life or limb threatening emergencies. Eschar is stiff, dead tissue caused by deep burns. Based on the severity of the burn alone, or as edema develops during the resuscitation phase, the inelastic eschar can cause an increase in tissue pressures that can impede critical physiology. Circumferential eschar on a limb, neck or penis restricts distal circulation, and eschar on the thorax restricts respiration. An escharotomy is a potentially limb/life-saving procedure performed by making an incision through the eschar, in length and depth, to release pressure, thereby restoring distal circulation and/or allowing for adequate oxygenation and ventilation.

Escharotomy is usually done within the first 2 to 10 hours of a burn injury. Unlike fasciotomies, where incisions are made specifically to decompress tissue compartments, escharotomy incisions do not breach the deep fascial layer, unless there is obvious pressure in the muscle compartments, then a fasciotomy must be done as well. This is typically the case with high-voltage electrical injuries. The incision is made through the non-viable eschar, allowing the cutaneous envelope to become more compliant, improving ventilation and oxygenation, and establishing reperfusion to the affected limb(s).

**Important Note:** Escharotomy is normally performed in the setting of circumferential full thickness burns. If the burn is superficial or less than circumferential, and pulses are absent, first rule out shock physiology, other causes of hypotension, and hypothermia.

## Indications & Contraindications

Circumferential full thickness burns of the chest, abdomen, neck, penis or limbs with respiratory or circulatory compromise. Escharotomy goes through the skin in depth and in length. The incision must be deepened through fat when required for complete release. Muscle compartments must be released with fasciotomies if they are tight after releasing the skin and fat.

Consultation with a burn surgeon, trauma surgeon or intensivist should be considered prior to performing an escharotomy. Escharotomy is not indicated in burns that will heal without surgical reconstruction (superficial or mid-dermal burns) and when there is no compromise to respiration or circulation.

### Indications specific to limb

---

Escharotomy is indicated when circulation is compromised due to increased pressure in the burnt limb and cannot be relieved by conservative measures. Elevation of the burnt limb should always be done first and then closely monitored. It is recommended that the procedure is performed before the pulses are absent. Signs that may indicate the need for an escharotomy may include:

- Loss of circulation
- Significant tightness
- Pallor or cyanosis
- Reduced or absent capillary refill in relation to capillary refill in unburnt areas
- Coolness
- Loss of palpable pulses (late sign)
- Numbness
- Decreased O2 saturation
- Decreased pulse pressure measured by doppler ultrasound

For any circumferential extremity (including digits) burn, hourly monitoring is essential. The extremity should be elevated as high as feasible, especially during transport. Palpable radial pulses do not exclude digital compartment syndrome; if feasible, assess the palmar arch and digital arteries with doppler. In general, a palpable pulse at the radial, dorsalis pedis and posterior tibialis is sufficient evidence of peripheral circulation in the absence of distal burns. Absent doppler signals or pulses that are diminishing on hourly exams should prompt consultation with a burn surgeon; strongly consider surgical decompression with escharotomy

## Indications specific to chest

---

Escharotomy should be considered when a circumferential burn of the chest wall or abdomen restricts chest wall movement and results in respiratory compromise. Under some circumstances escharotomy may be necessary for near circumferential burns of the chest wall if chest wall movement is restricted.

Circumferential burns of the abdomen predispose to abdominal compartment syndrome and may also cause respiratory compromise by restricting diaphragmatic movement as well as obstructive shock physiology from IVC compression. Infants under 12 months are particularly vulnerable since respiration is predominantly diaphragmatic. Under these circumstances a sub-diaphragmatic transverse escharotomy may be necessary.

Respiratory failure is defined as the inability to ventilate or oxygenate using maximal conventional ventilator parameters or bag-valve-mask technique. There are no definitive threshold values of PaCO<sub>2</sub> or PaO<sub>2</sub>/SpO<sub>2</sub>. ABG or SpO<sub>2</sub> threshold values must be taken into consideration of the

totality of the situation (e.g. inhalation injury, concurrent trauma, etc.)

Consultation with an intensivist is recommended to help define these thresholds for respiratory failure.

Consider chest escharotomy if there is:

- Circumferential full thickness burns of the thorax and abdomen that impede normal respiration
- Significant tightness
- Restricted movement of the chest wall or abdomen
- High ventilator pressures
- Reduced air entry bilaterally
- Shallow respiratory effort
- Tachypnea
- Hypoxemia

Once the escharotomy is performed, monitor for improvement in oxygenation and ventilation as evidenced by improved compliance when using a mechanical ventilator or bag-valve device, visible chest rise, and normalizing P<sub>a</sub>O<sub>2</sub> and PCO<sub>2</sub>.

## Instruction on Performance

### Before Beginning

The patient is placed in a supine position while maintaining ventilatory support efforts. Although full thickness burn is insensate, patients will require general anaesthesia or procedural sedation and analgesia during this procedure. Time permitting – cleanse the area of any excess debris or loose clothing. The procedure can be done in the emergency department, in ICU or in the OR.

### General Considerations

Escharotomy should be done in a stepwise fashion by doing one incision on one side of the extremity and then reassessing the limb condition. If there is no improvement, another opposing incision can be made.

The incision can be done either by a scalpel or cautery and hemostasis can be maintained by coagulation cautery (Note: Using electrocautery to perform escharotomy reduces bleeding compared to a scalpel). Extend escharotomy incisions the entire length of the circumferential portion of a full-thickness burn. It should be deep enough to achieve full relaxation of the tissue. Care should be taken not to injure any of the deep structures especially nerves, and not to cross any of the flexor creases.

Carry incisions across involved joints.

On completion of the escharotomy, reassess perfusion. If circulation is restored, bleeding should be controlled with electrocautery and-or ligating bleeding vessels, when

necessary. The area is then dressed and elevated at a 30-45° angle when possible. Assess pulses hourly for at least 12-24 hours.

### Limbs

- In the upper extremities, place the hand in the anatomic position (palm facing forward) and make an incision in the mid-axial line bilaterally (see schemas below), i.e. mid radial or mid ulnar line, carrying the incision up the arm. Ulnar incisions should stay anterior (volar) of the elbow joint to avoid the ulnar nerve, which is superficial at the level of the elbow. If both the hand and arm are burned, continue the incision across the mid ulnar or mid radial wrist and onto the hand. If circulation is not restored, perform a second incision on the opposite side of the extremity. When indicated, a carpal tunnel release should be performed.
- If finger escharotomies are required, avoid functional surfaces (radial surface of the index finger and ulnar surface of the little finger). Place the fingers in a clenched position and note the finger creases at distal interphalangeal and proximal interphalangeal joints. Escharotomy incisions should be just dorsal to a line drawn between the tops of these creases

## Chest

Incise along the mid axillary lines, continuing over the abdominal wall if the burn extends to this region.

- Start and finish the incision one centimeter into unburnt healthy tissue where possible. Use local anaesthetic for the unburnt skin if general anaesthesia is not provided.
- If improved compliance is not seen after the initial incision, revise the escharotomy to improve ventilatory support. Consider joining the vertical incisions with two transverse incisions. The transverse incisions connect the previous vertical incisions made above. The first is at the clavicles inferiorly and the second is superior to the abdomen at the level of the costal margin.
- Once completed, cover the torso with a sterile burn sheet.
- Maintain continuous monitoring of the patient's respiratory compliance and oxygenation

## General Notes

The use of blood products in major burn resuscitation due to coagulopathy, anemia, and bleeding from escharotomy sites or other traumatic injuries is common. Following escharotomy, bleeding may occur as circulation is restored. Examine the surgical site every few minutes for up to 30 minutes for signs of new bleeding, which is easily controlled with electrocautery.

Refer to the Provincial Major Burns Trauma Clinical Practice Guidelines for transfusion guidelines and resuscitation of patients with major burns.

[https://emergencycarebc.ca/clinical\\_resource/clinical-summary/major-burns-trauma/](https://emergencycarebc.ca/clinical_resource/clinical-summary/major-burns-trauma/)



## What to avoid

Avoid incisions across the flexor creases of joints – incisions of the limbs are in the mid-axial lines between flexor and extensor surfaces. Mark anatomical at-risk areas prior to making any incisions. See schema for areas to avoid.

### Lower limbs

Medial:

Avoid the posterior tibial arteries and nerves, greater saphenous vein and saphenous nerves.

Incision should pass posterior to the medial malleolus.

Lateral:

Avoid the common peroneal nerve at the head of the fibula.

Incisions are made anterior to the head of the fibula.

### Upper limbs

Medial:

Avoid the ulnar nerve at the elbow.

Incision should pass anterior to the medial epicondyle.

### Neck

Avoid carotid arteries and external jugular veins.

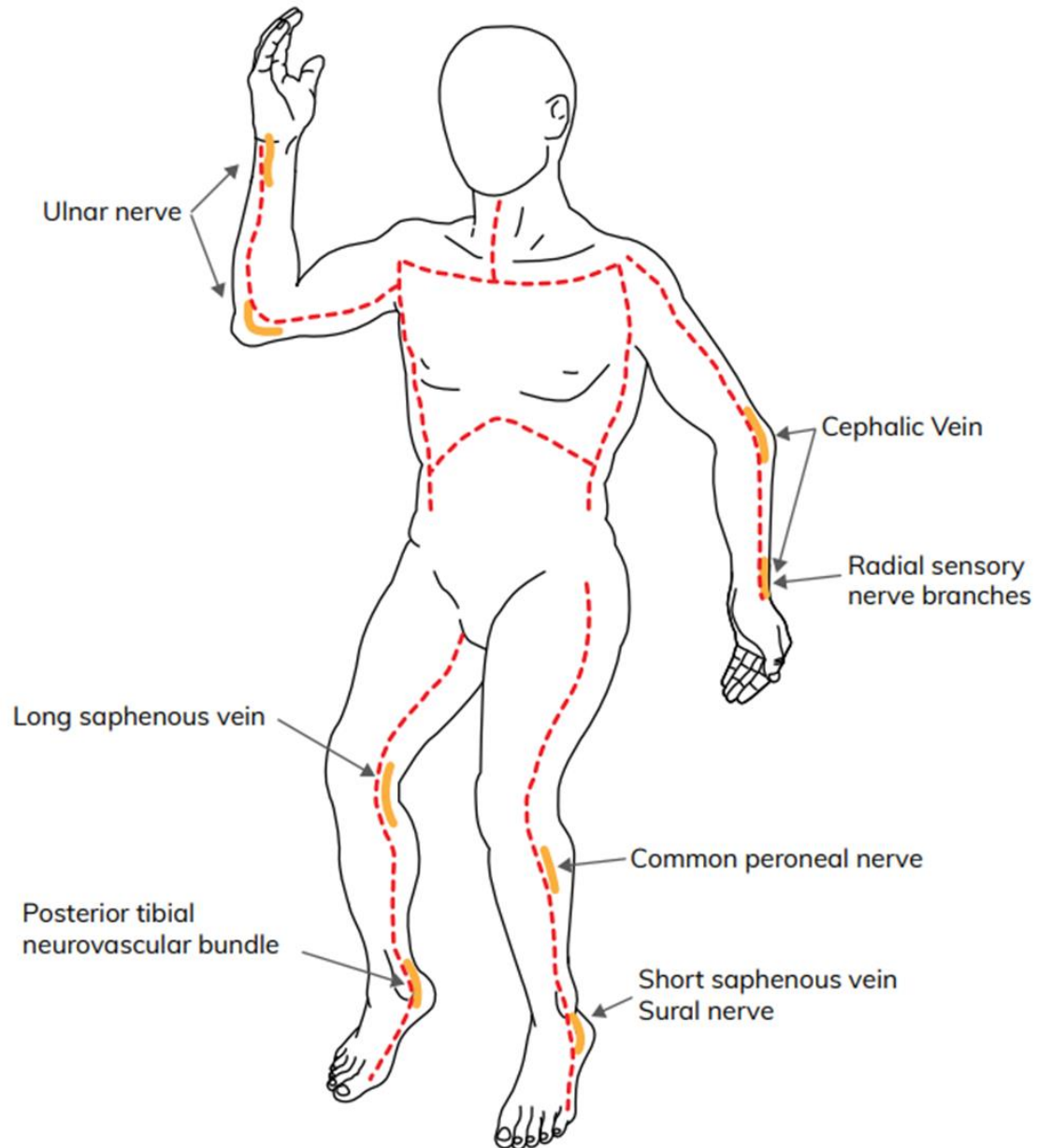
### Risks and complications

- Bleeding
- Infection
- Damage to underlying neurovascular structures
- Inadvertent fasciotomy
- Failure to detect a fascial compartment syndrome after escharotomies are done.

**CAUTION**  
Identify and avoid important structures

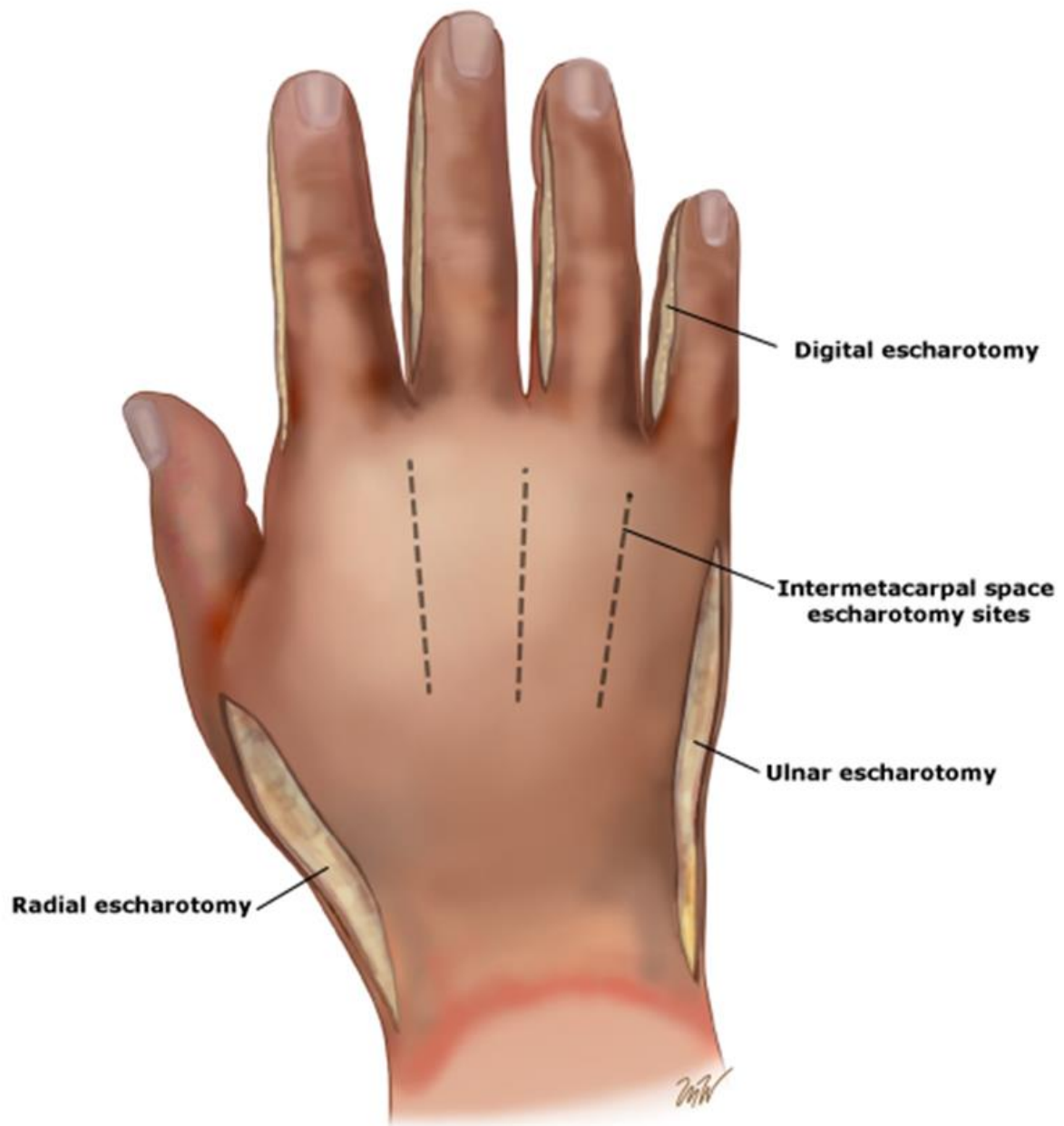
## Escharotomy Schema-body

**Dashed lines** indicate the preferred sites for escharotomy incisions. **Bold lines** indicate the importance of extending the incision over involved major joints.



Agency for Clinical Innovation; New South Wales Government, (2024).

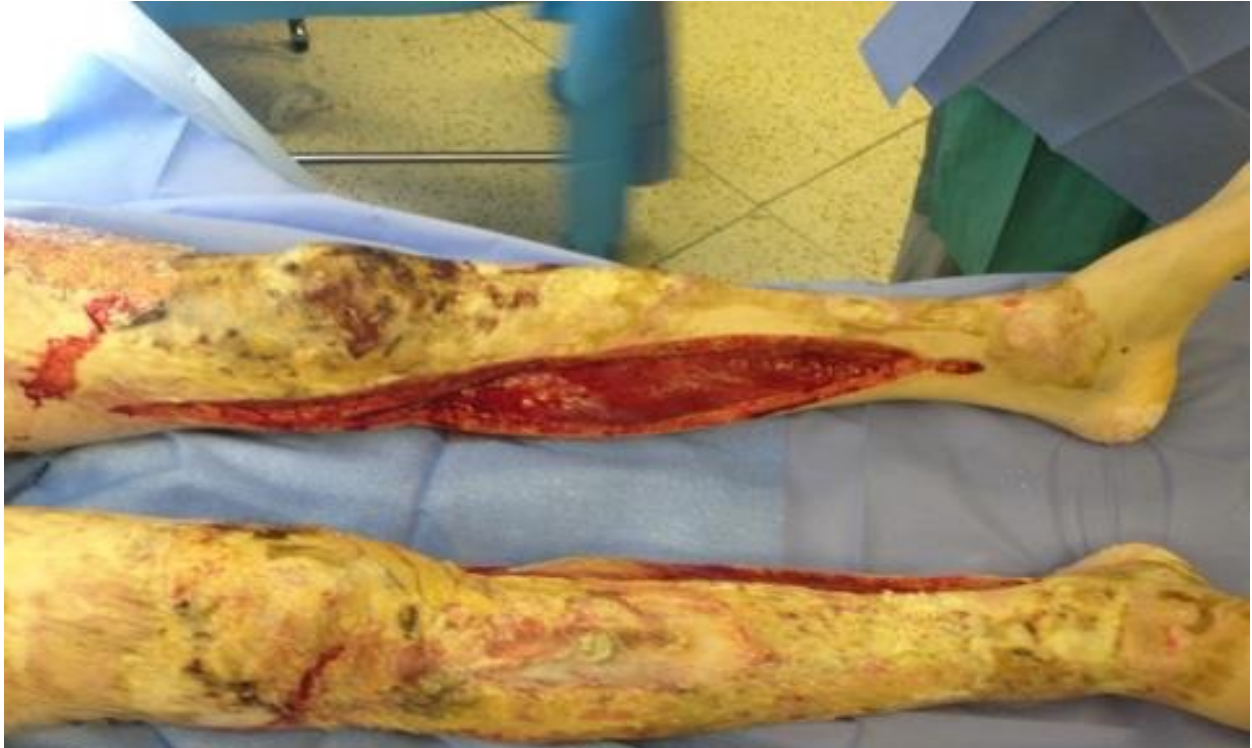## Escharotomy Schema hand



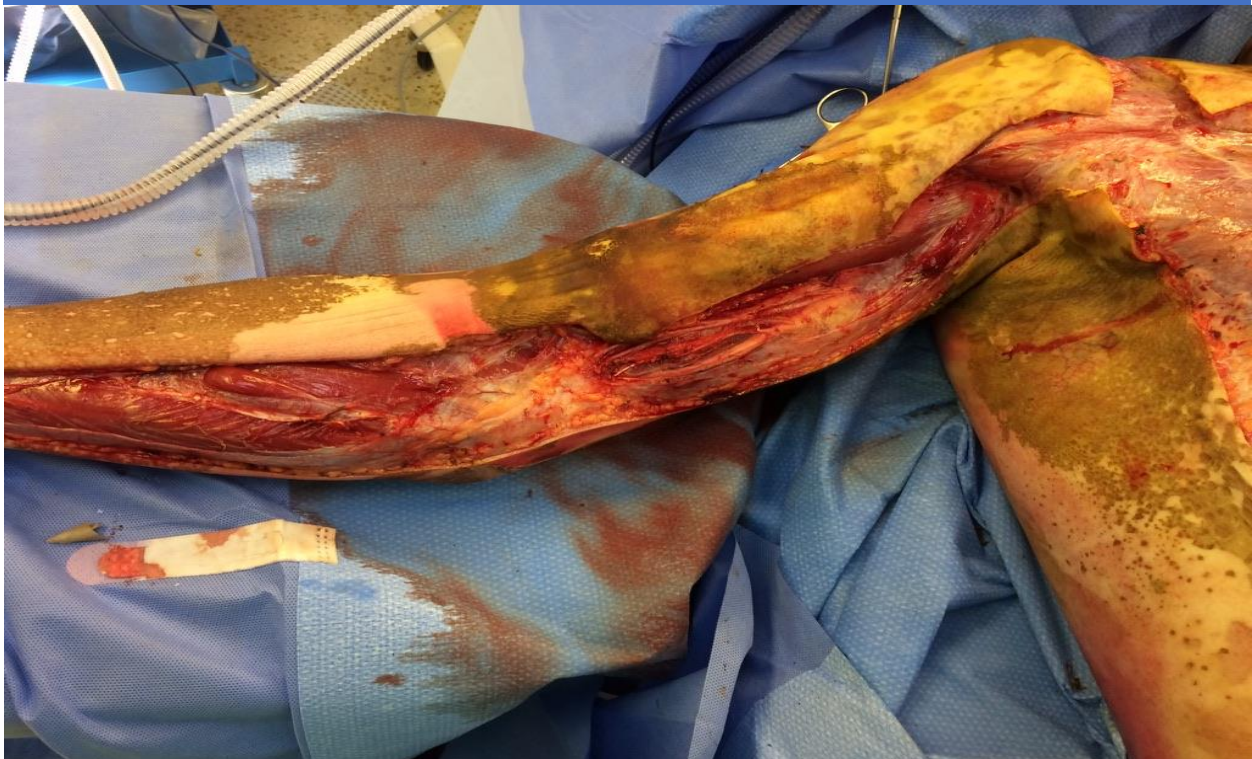Graphic 64145 Version 2.0 © 2024 UpToDate, Inc. and/or its affiliates. All Rights Reserved

## Step-by-step Procedure for performing an escharotomy

Procedure			
1	Sterile procedure with adequate drapes. Don PPE.	6	Ensure incision is on both sides of limb or chest to restore circulation.
2	Draw a line where you will make the incision.	7	Ensure adequacy of the incisions by reassessing circulation or respiration. There should be a noticeable separation and relief of pressure from tight 'tourniquet' effect of burn.
3	Insert local anaesthetic into normal skin where incision will continue 1cm past the edge of the burn.	8	Have electrocautery or ligatures available for hemorrhage control.
4	Perform full thickness incision, using scalpel or electrocautery device, into subcutaneous fat sufficiently to see obvious relaxation of tissue.	9	Dress wounds with Flamazine/silver dressings, gauze and circumferential bandage.
5	Run a finger along the incision to detect residual restrictive areas.	10	Continue to assess limb circulation and/or chest expansion to ensure the procedure is effective.



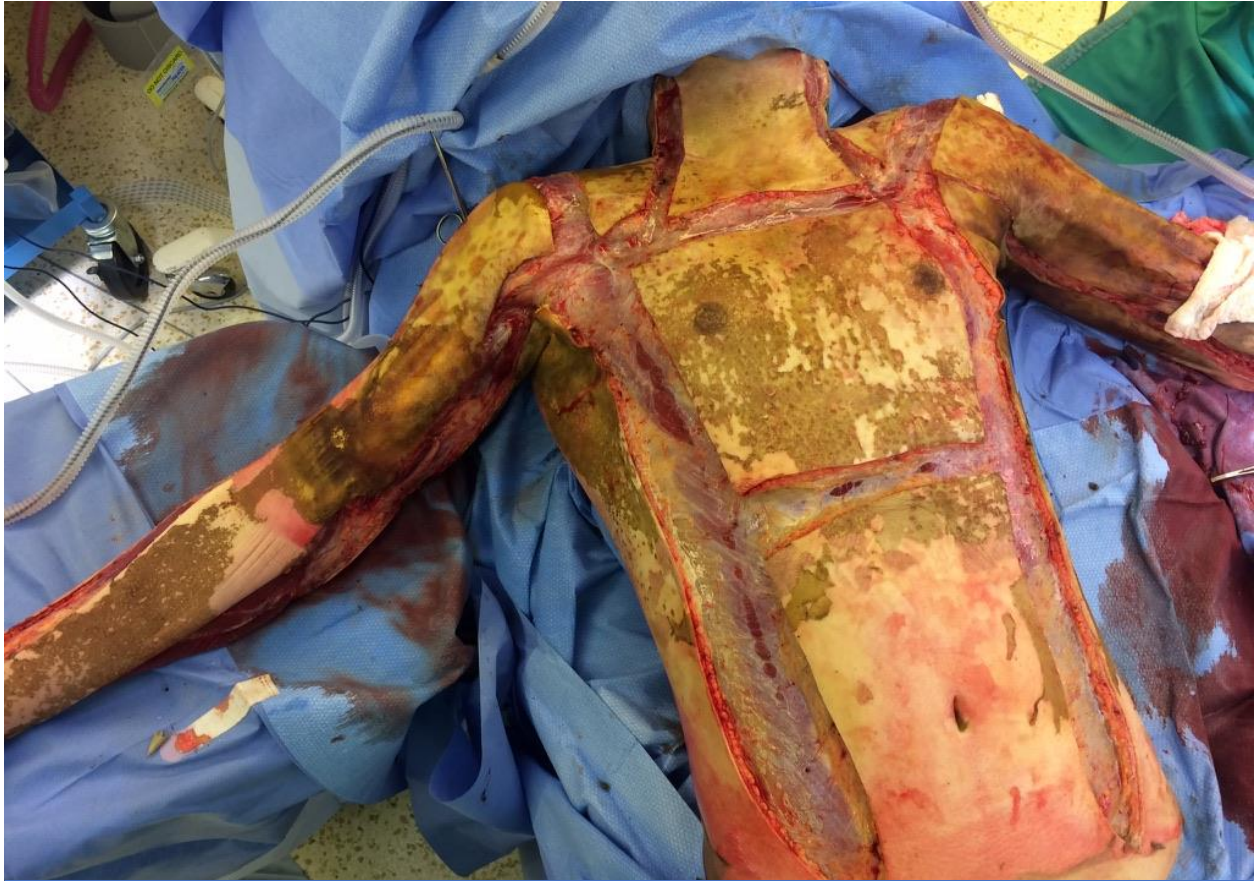Incision of lower limb



Incision of upper limb

Papp, A. (2025). *Upper and Lower Limb Escharotomy*.





Escharotomy of chest, abdomen, and upper limbs

Papp, A. (2025). *Escharotomy of chest, abdomen, and upper limbs*.

## Escharotomy factsheet

### Aim

To release rigid and inelastic burnt skin known as eschar to allow circulation to a limb or penis, or oxygenation and ventilation when the thorax is involved, before problems arise, or to treat an existing problem.

### Indications

Circumferential partial or full thickness burns of the chest, abdomen, neck, penis or limbs with respiratory or circulatory compromise. Note: Burns to the chest may not necessarily be circumferential to impede respiration, particularly in paediatric patients.

### Environment

May be performed in the operating room under general anaesthesia but may also be done in the emergency department or intensive care unit under general anaesthesia, procedural sedation and analgesia, or with local anaesthetic.

### Equipment

- |                                       |   |   |
|---------------------------------------|---|---|
| ○ Sterile drapes                      | ○ Ligature                                    | ○ Dressing e.g. Flamazine/silver dressing, gauze                    |
| ○ Skin prep                           | ○ Local anaesthetic (with syringe and needle) |   |
| ○ Personal protective equipment (PPE) | ○ Scalpel/electrocautery                      | ○ Outer non-stick dressing (i.e. gauze and circumferential bandage) |
| ○ Surgery marker                      | ○ Dressing pack                               |   |

### Procedure

- Sterile procedure with adequate drapes. Don PPE.
- Draw a line where you will make the incision.
- Insert local anaesthetic into normal skin where incision will continue 1cm past the edge of the burn.
- Perform full thickness incision, using scalpel or electrocautery device, into subcutaneous fat sufficiently to see obvious relaxation of tissue.
- Run a finger along the incision to detect residual restrictive areas.
- Ensure incision is on both sides of limb or chest to restore circulation.
- Ensure adequacy of the incisions by reassessing circulation or respiration. There should be a noticeable separation and relief of pressure from tight 'tourniquet' effect of burn.
- Have electrocautery or ligatures available for hemorrhage control.
- Dress wounds with Flamazine/silver dressings, gauze and circumferential bandage.
- Continue to assess limb circulation and/or chest expansion to ensure the procedure is effective.

### Post-escharotomy care

- Loosely pack incisions with sterile gauze
- Continue monitoring circulation to limbs, as well as oxygenation, ventilation, and ventilatory pressure.
- Elevate limbs.
- Continue burn care and calculated resuscitation
- Monitor bleeding.

**Caution**  
**Avoid important structures**  
See schema

## References

1. New South Wales Government, Statewide Burns Injury Service, Clinical Guidelines, Escharotomy for Burn Patients, 2019
2. International Society for Burn Injury Practice Guidelines Committee. *ISBI Practice Guidelines for Burn Care*. Burns. 2016;42(5):953-1021.
3. Joint Trauma System Clinical Practice Guidelines, *Burns Care (CPG ID:12)*, 2023.
4. Joint Trauma System Clinical Practice Guidelines, *Burn Wound Management in Prolonged Field Care (CPG ID:57)*, 2017.
5. Streitz MJ, *How to do a burn escharotomy*, Merck Manual Professional Version, 2023.
6. <https://www.uptodate.com/contents/emergency-care-of-moderate-and-severe-thermal-burns-in-adults?source=Out%20of%20date%20-%20zh-Hans>
7. Burns, E. (2014). *Build your own escharotomy man*. Clinical Governance Day Flyer. Greater Sydney Area Helicopter Emergency Medical Service. <https://sydneyhems.com/2014/08/30/build-your-own-escharotomy-man>.
8. Papp, A. (2025). *Escharotomy of chest, abdomen, upper, and lower limbs*. [photograph(s)].